

Downsizing – the Future of Interventional Cardiology

Giovanni Amoroso

Interventional Cardiologist, Department of Cardiology, Onze Lieve Vrouwe Gasthuis Amsterdam

Abstract

The concept of downsized catheters (i.e., using catheters smaller than 6 French) for invasive coronary procedures, such as diagnostic cardiac catheterisation and percutaneous coronary intervention, has been developing over the years, particularly as a result of the rise of the transradial approach. Recent advances have allowed the use of smaller and sheathless catheters, which confer a number of advantages – such as fewer vascular complications, reduced use of contrast agent and reduced haemostasis – thus increasing patient safety and comfort and allowing more rapid patient mobilisation. Reductions in patient complications, number and length of hospital stay, and amount of contrast agent used can also lead to cost savings. While the use of smaller catheters has been hindered in the past because of poor angiographic image quality, new automated contrast injectors have helped overcome this limitation. There is a need to make interventional cardiologists worldwide more aware of the benefits of downsizing, in the light of the latest technical developments and the increased use of transradial approach.

Keywords

Automated contrast injection, catheter, diagnostic cardiac catheterisation, downsizing, percutaneous coronary intervention, transradial approach

Disclosure: The author has no conflicts of interest to declare.

Received: 23 January 2012 **Accepted:** 12 February 2012 **Citation:** *Interventional Cardiology*, 2012;7(1):28–32

Correspondence: Giovanni Amoroso, Afdeling Cardiologie, Onze Lieve Vrouwe Gasthuis, Postbus 95500, 1090 HM Amsterdam, The Netherlands. E: G.Amoroso@olvg.nl

Support: The publication of this article was funded by ACIST. The views and opinions expressed are those of the author and not necessarily those of ACIST.

The increased incidence of coronary artery disease, as well as the advances in device technology and improved potentialities of percutaneous coronary intervention (PCI), have resulted in a dramatic rise in the number of invasive coronary procedures (both diagnostic catheterisations and PCIs).¹ These procedures normally used the transfemoral access, which involves the insertion of a catheter through the femoral artery. However, the transradial access route, where the catheter is inserted through the radial artery, is rapidly emerging as a safe and effective alternative to the femoral approach.

Several studies have shown that the radial approach allows treatment of the same type of patients and lesions as the femoral approach, but with several advantages.² The Radial vs femoral access for coronary intervention (RIVAL) study showed, for instance, that the transradial approach is associated with a lower rate of local vascular complications in the overall population, and a reduction in mortality in the setting of acute PCI.³ The radial approach also allows earlier mobilisation of the patient. Following femoral access procedures, a period of recumbence is required to avoid disruption of the arterial puncture site. This may be poorly tolerated by patients with left ventricular dysfunction, lung disease, or back and/or hip pain. The superficial course of the distal radial artery allows easy compression (manually or via a device) of the artery. As a result, patients are able to move immediately and may be discharged the same day.^{2–5}

However, the greater technical complexity of transradial access procedures has, until recently, limited their use. Since the radial artery

has a smaller internal diameter than the femoral artery, to achieve artery cannulation and to successfully use smaller catheters requires, even for experienced specialists, going through a steep learning curve.⁶ Catheter manipulation is particularly cumbersome when the ratio between the radial artery's inner diameter and the catheter's outer diameter is smaller than 1.

Currently, the standard combination for coronary diagnostic and intervention procedures is a 6 French (Fr) catheter and a 6 Fr compatible introducer. However, in a Japanese study (n=250), 20 % of male patients and 40 % of female patients had a radial artery inner diameter smaller than, or equal to, the outer diameter of a 6 Fr compatible introducer (see *Figure 1*).⁷ Furthermore, procedural complications associated with the transradial route increase with the size of introducer used;⁸ these complications, which range from temporary arterial spasm to permanent arterial occlusion, may be reduced with the use of downsized catheters.

Downsizing in interventional cardiology refers primarily to the use of catheters and sheaths that are smaller in diameter than the current standard. A 4 or 5 Fr catheter (plus introducer) is thus considered a downsized catheter. The so-called sheathless catheters also fall into the category of downsized catheters because they can be used without an introducer, which is usually 1–2 Fr sizes bigger in (outer) diameter than the corresponding catheter. Hence one can, for example, refer to a 'sheathless' 5 Fr procedure as a 'virtual' 3 Fr procedure.

This article will discuss the benefits of the downsizing approach (in particular when combined with transradial access), barriers to its successful implementation and strategies to overcome these barriers.

The Benefits of Downsizing

Downsizing from large diameter catheters, such as 8 Fr catheters, to the now-standard 6 Fr catheters has been associated with a number of favourable clinical and procedural outcomes, even when the transfemoral route was used. A large retrospective study in Michigan (n=103,070) compared outcomes in patients who underwent PCI using 6 Fr, 7 Fr and 8 Fr catheters. PCIs performed with 7 and 8 Fr catheters were associated with vascular complications (odds ratio [OR] for 7 Fr catheters: 1.19, $p=0.0002$; OR for 8 Fr catheters: 1.68, $p<0.0001$), with decline in haemoglobin >3 g/dl (OR for 7 Fr catheters: 1.12, $p<0.0001$; OR for 8 Fr catheters: 1.72, $p<0.0001$) and with post-procedure blood transfusion (OR for 7 Fr catheters: 1.08, $p=0.03$; OR for 8 Fr catheters: 1.80, $p<0.0001$).⁹

When using the transfemoral approach, reducing catheter size has been shown to result in early ambulation and enhanced comfort, without significantly reducing the quality of coronary angiography.⁹⁻¹² Clinical trials have shown a lower arterial puncture-related morbidity rate when the catheter diameter is reduced from 8 to 4 Fr.¹³⁻¹⁵ Diagnostic coronary angiography has therefore been attempted for several years using 4 Fr catheters.^{16,17}

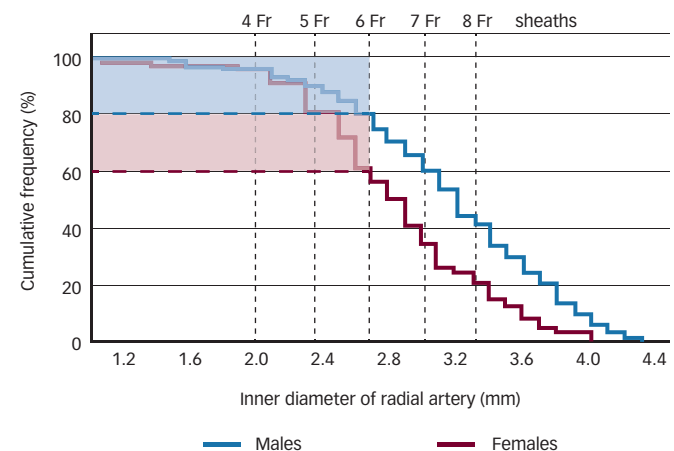
Furthermore, there are certain clinical situations in which a downsized catheter can be advantageous. Some severe calcified coronary lesions or tortuous vessels may resist the advancement of the stent due to a lack of support of the guiding catheter. In such cases, switching from a 6 Fr to 5 Fr catheter has been reported to allow a safe and deep engagement.^{18,19}

It has been demonstrated that downsizing leads to a reduction in the amount of contrast agent used and to shorter fluoroscopy time. Fluoroscopy time also improves with experience: when performing PCI with 4 Fr catheters, Takeshita et al. observed a significant reduction in fluoroscopy time (8 ± 6 minutes versus 17 ± 15 minutes, $p<0.05$) and in the amount of contrast dye used (64 ± 33 ml versus 90 ± 46 ml, $p<0.05$) between the early phase and the late phase of their experiment.²⁰ No access site-related complications were observed in either phase.

Reducing the amount of contrast agent used has a positive effect on safety, as it lowers the risk of contrast-related allergy. Furthermore, the use of contrast may be associated with contrast-induced nephropathy (CIN), a frequent cause of hospital-acquired acute or chronic renal insufficiency in patients undergoing cardiac catheterisation and PCI.²¹ CIN incidences of 14 % have been reported in patients undergoing PCI, with a substantial increase in in-hospital mortality.²² In the Michigan study, larger catheter sizes were associated with a higher amount of contrast used and a higher risk of CIN (OR for 7 Fr catheters: 1.18, $p=0.0004$; OR for 8 Fr catheter: 1.44, $p<0.0001$).⁹

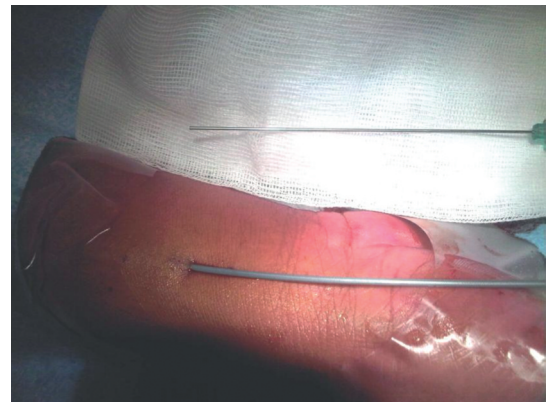
Because of its smaller inner diameter, the radial artery can seldom accommodate catheters larger than 6 Fr. Therefore, the use of the transradial route, compared with the transfemoral route, represents in itself a way of downsizing, the operators being forced to use 6 Fr catheters at the most.

Figure 1: Cumulative Frequency of Radial Artery Diameter and its Relationship to (Sheath) Outer Diameter



In a Japanese study, 20 % of male patients and 40 % of female patients had a radial artery inner diameter smaller than, or equal to, the outer diameter of a 6 French (Fr) compatible introducer. Source: Saito et al., 1999.⁷

Figure 2: Example of Radial Artery Cannulation with a 5 F Sheathless Guiding Catheter (Medikit Co Ltd, Tokyo)



Further downsizing could potentially make the transradial approach successful in 100 % of patients. The use of smaller catheters (4 or 5 Fr) as well as sheathless ones – and ideally the combination of both^{8,23-25} – reduces the risk and/or extent of trauma to the radial artery, particularly in patients who have a narrow radial artery, thereby not only reducing patient discomfort²⁶ but also leading to fewer bleeding complications and occlusions of the radial artery²⁷ (see Figure 2). Radial artery occlusion has been reported in approximately 5 % of patients following transradial artery coronary angioplasty, and its occurrence is higher in case of catheter–artery mismatch and/or prolonged compression.²⁸

The use of a downsized catheter combined with a transradial approach results in a smaller incision to the wrist, and therefore less trauma and a shorter period of haemostasis.²⁷ When operators are careful to keep perfusion into the radial artery during arterial compression ('patent' haemostasis), not only is the risk of radial artery occlusion further reduced,²⁹ but also arterial compression can be stopped earlier.

There are considerable data to support the premise that the use of smaller guide catheters, whether transfemoral or transradial, may result in enhanced clinical outcomes in patients undergoing PCI. As well as benefits in terms of patient safety and comfort, the use of downsized catheters for interventional cardiology also

Figure 3: ACIST CVi contrast delivery system

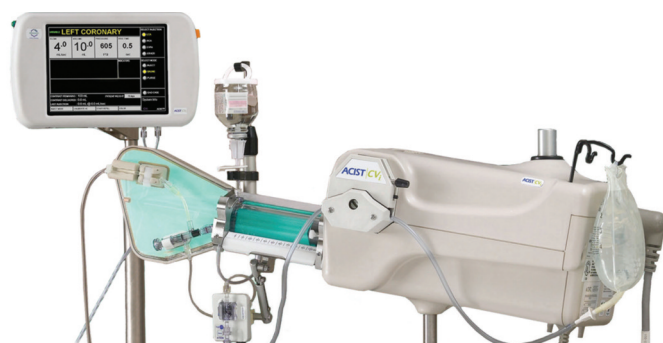

Figure 4: ACIST Angiotouch hand controller



has significant financial advantages. Reduced patient ambulation time means same-day discharge and a higher patient turnover. Reducing the amount of contrast agent used, reducing patient complications and avoiding the use of closure devices can lead to further cost savings.^{30–34}

Implementing the Downsizing Approach

The advantages of downsized catheters are evident from the above. However, there are also limitations to the downsizing approach. Smaller catheters are more difficult to handle: a comparison between 4 Fr and 5 Fr catheters for diagnostic coronary angiography showed a statistically significant difference in favour of the 5 Fr catheters regarding manoeuvrability subjectively assessed by the primary operator on a questionnaire (93 % versus 79 %, $p < 0.001$).¹⁷

Another potential barrier to the use of smaller catheters in PCI is the unavailability of compatible balloons, filters, wires and stents; such

additional devices would have originally been designed to be compatible with the standard 6 Fr catheters; it should be noted, however, that many of the newer ones are also compatible with 5 Fr catheters. In a recently published all-comers study, based on lesion/device compatibility, 50 % or more of the patients could actually have been treated with a 5 Fr catheter instead of a standard one.³⁵ For diagnostic procedures, which do not require additional devices, there is no such barrier.

It should be borne in mind that, 10 years ago, a move to the use of 6 Fr catheters was considered downsizing, but that 6 Fr catheters are now the worldwide accepted standard. In Japan, the 'Slender Club', made of cardiologists and device companies devoted to the 'downsizing' philosophy, is busy developing devices that can be compatible with both 4 and 5 Fr catheters; it is anticipated that such products will soon be available in Europe and the US.

While the use of smaller catheters, and thus of less contrast agent, has its benefits, an important consideration for the interventional cardiologist, when choosing the catheter size, is whether the visualisation of the coronary artery and the quality of the procedure will be as good, if not better, with a smaller catheter than with a standard one. The visualisation of the coronary artery may be limited when using a small diameter catheter, because it depends on the amount of contrast agent injected – the smaller the catheter, the less contrast agent injected, the poorer the visualisation. The use of catheters smaller than 5 Fr has been hindered by technical issues, such as variable or suboptimal catheter handling and angiographic image quality, when using the traditional manual injection technique.^{16,36}

To overcome some of the potential limitations of downsizing, automated contrast injectors (ACIs), such as the ACIST CVi™ Contrast Delivery System (see Figure 3), have been developed. Such advanced contrast delivery systems may help overcome the limitations of delivering contrast with a hand syringe and a patient manifold.^{11,12,37} The ACIST system has been developed to facilitate contrast injection in all angiography procedures. It features a pneumatic hand controller (see Figure 4) that allows the operator to control the flow and volume of contrast media directly from the sterile field. The ACIST system is an operator-assisted, variable-flow contrast delivery system that enables the operator to customise the flow and volume of contrast agent to be injected, thereby ensuring that the contrast agent is delivered precisely and predictably.³⁸

Coronary angiography trials via the femoral route have verified the benefits of the ACIST Contrast Delivery System. By reducing the overall procedure time, the ACIST system helps to reduce radiation exposure.³⁹ The use of a hand controller to inject contrast allows the operator to increase the distance between the X-ray source and the patient, potentially reducing the radiation dose received by the operator. Compared with the use of standard catheters alone, the combined use of downsized catheters and a variable-flow contrast delivery system has been shown to result in improved visualisation and similar or better quality interventional cardiology procedures^{11,12,16,40–43} (see Figure 5). In a prospective, single-centre randomised pilot trial comparing an 6 Fr catheter and manual injection with an 4 Fr catheter and the ACIST system, coronary angiographic quality scores were equivalent between the two techniques (left coronary artery: 4.73 ± 0.6 versus 4.80 ± 0.65 , $p = 0.28$;

right coronary artery; 4.98 ± 90.13 versus 4.97 ± 0.16 , $p=0.48$) on a scale from 1 to 5 (1 = poor; 3 = marginally diagnostic; 5 = optimal). The total study contrast volume was significantly smaller in the 4 Fr group (119 ± 35 ml versus 159 ± 52 ml, $p=0.001$) (see Figure 6).¹² In another study comparing 4 Fr and 6 Fr catheters used with the ACIST system, the quality of the angiographic runs obtained with 4 Fr catheters was evaluated as satisfactory or excellent in 85 % of cases.⁴² In a comparative study of 4 Fr catheters used with the ACIST system versus hand-manifold 6 Fr catheters in 1,816 patients undergoing coronary angiography, the 4 Fr catheters achieved an acceptable diagnostic quality while simultaneously reducing contrast media consumption and radial artery injury.⁴⁴

The variable-flow contrast delivery technique is safer, cleaner and simpler than manual injection because there is no unnecessary use of contrast and thus less contrast-related adverse events. In an Israeli study comparing traditional manual injection of contrast with the ACIST system ($n=453$), the latter used a significantly smaller volume of contrast.⁴⁵ The difference was largely attributable to a reduction in waste, but there was also a decrease in per-patient contrast volume of up to 25 %. Another study ($n=450$) showed an up to 39 % reduction in contrast volume when using the ACIST system compared with manual injection (100 ± 42 ml versus 163 ± 56 ml, $p<0.001$, respectively), as well as a significant reduction in fluoroscopy time.³⁹ A time and motion study found that power contrast injection was more efficient than manual injection, resulting in a 31 % reduction in set-up and procedure time (see Figure 7).³¹

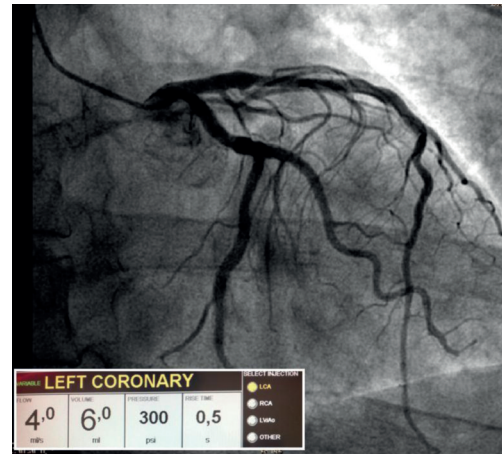
Automated injection has also been shown to result in a significant reduction in CIN. The incidence of CIN was assessed in 1,798 patients after diagnostic catheterisation or PCI using traditional manual injection systems, and in 377 subsequent patients after diagnostic catheterisation or PCI using an automated contrast injection system. CIN occurred less often in the automated injection group than in the manual injection group (13.3 % versus 19.3 %, respectively, $p<0.05$), corresponding to a 31.1 % reduction in the incidence of CIN.⁴⁶

As well as bringing advantages in terms of image quality and safety, the use of variable-flow injection techniques will ultimately lead to cost savings, as they require less personnel (usually one operator is enough), avoid any unnecessary use of contrast and allow early ambulation.^{11,12}

Conclusion

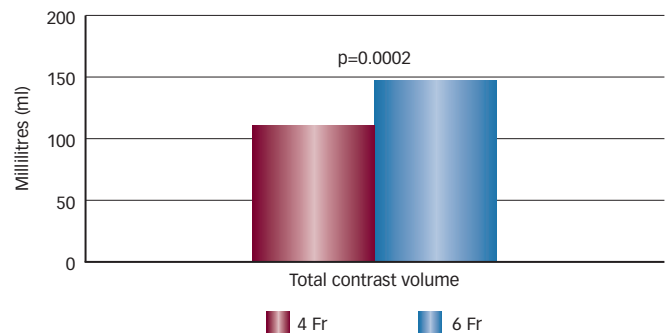
There has been a long-term trend towards downsizing in interventional cardiology, but the fast and diffuse adoption of the transradial approach has emphasised it. While downsizing is not a new concept in itself, there are still certain barriers to its complete and successful implementation in interventional cardiology procedures. While it is true that most procedures can be successfully performed with standard 6 Fr catheters, it is important to raise awareness of the additional benefits that downsized catheters can provide, such as cost savings and increased patient safety and comfort. Further development of coronary devices and the use of automated contrast injection systems can help overcome the present limitations of downsized catheters (i.e., device incompatibility and poor coronary visualisation).

Figure 5: Example of Coronary Angiography Using a 4 Fr Catheter and the ACIST CVi™ Contrast Delivery System



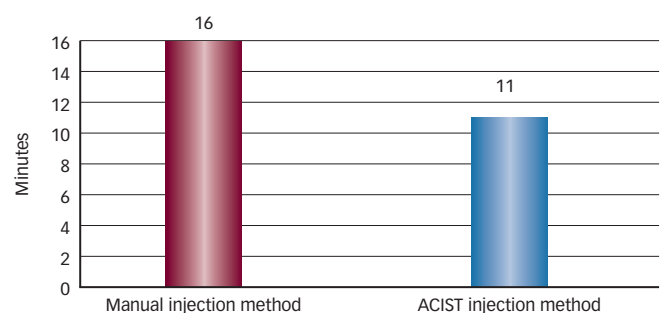
The panel on the bottom left shows the device settings; from left to right: flow rate 4,0 ml/s, volume 6,0 ml, pressure 300 psi, delay 0.5 seconds.

Figure 6: Amounts of Contrast Volume Used During 4 Fr and 6 Fr Diagnostic Coronary Procedures



In a pilot trial comparing an 6 French (Fr) catheter and manual injection with an 4 Fr catheter used with the ACIST CVi™ Contrast Delivery System, the total contrast volumes were significantly smaller in the 4 Fr group. Source: Khoukaz et al., 2001¹²

Figure 7: Procedural Hands-on Time per Patient for Manual Injection and ACIST Injection Method



Source: Lehmann et al., 2005.³¹

There needs to be a paradigm shift towards using the downsizing approach. Medical institutions that have experience with both transradial approach and downsizing bear the responsibility to share their expertise and collaborate with starting centres. There will be a need for further training of interventional cardiologists, as the use of downsized catheters requires practice and expertise. These should be seen as opportunities, rather than limitations, to set new and higher standards in patient care. ■

- Cook S, Walker A, Hügli O, et al., Percutaneous coronary interventions in Europe: prevalence, numerical estimates, and projections based on data up to 2004, *Clin Res Cardiol*, 2007;96:375–82.
- Kiemeneij F, Laarman GJ, Odekerken D, et al., A randomized comparison of percutaneous transluminal coronary angioplasty by the radial, brachial and femoral approaches: the access study, *J Am Coll Cardiol*, 1997;29:1269–75.
- Jolly SS, Yusuf S, Cairns J, et al., RIVAL trial group, Radial versus femoral access for coronary angiography and intervention in patients with acute coronary syndromes (RIVAL): a randomised, parallel group, multicentre trial, *Lancet*, 2011;377:1409–20.
- Amoroso G, Kiemeneij F, Transradial access for primary percutaneous coronary intervention: the next standard of care?, *Heart*, 2010;96:1341–4.
- Amoroso G, Laarman GJ, Kiemeneij F, Overview of the transradial approach in percutaneous coronary intervention, *J Cardiovasc Med (Hagerstown)*, 2007;8:230–7.
- Ball WT, Sharieff W, Jolly SS, et al., Characterization of operator learning curve for transradial coronary interventions, *Circ Cardiovasc Interv*, 2011;4:336–41.
- Saito S, Ikei H, Hosokawa G, Tanaka S, Influence of the ratio between radial artery inner diameter and sheath outer diameter on radial artery flow after transradial coronary intervention, *Catheter Cardiovasc Interv*, 1999;46:173–8.
- Mamas M, D'Souza S, Hendry C, et al., Use of the sheathless guide catheter during routine transradial percutaneous coronary intervention: a feasibility study, *Catheter Cardiovasc Interv*, 2010;75:596–602.
- Grossman PM, Gurm HS, McNamara R, et al., Blue Cross Blue Shield of Michigan Cardiovascular Consortium (BMC2), Percutaneous coronary intervention complications and guide catheter size: bigger is not better, *JACC Cardiovasc Interv*, 2009;2:636–44.
- Doyle BJ, Ting HH, Bell MR, et al., Major femoral bleeding complications after percutaneous coronary intervention: incidence, predictors, and impact on long-term survival among 17,901 patients treated at the Mayo Clinic from 1994 to 2005, *JACC Cardiovasc Interv*, 2008;1:202–9.
- Khoukaz S, Eisenhauer M, Valencia D, et al, Coronary Angiography Using 4Fr Power ACISTed Technique Compared to 6Fr Manual Injection Results of a Randomized Trial. Presented at: Society for Cardiac Angiography and Interventions meeting, May 2000, Charleston, South Carolina, US.
- Khoukaz S, Kern MJ, Bitar SR, et al., Coronary angiography using 4 Fr catheters with acisted power injection: A randomized comparison to 6 Fr manual technique and early ambulation, *Catheter Cardiovasc Interv*, 2001;52:393–8.
- Domingo E, Lupon-Rosés J, Angel J, et al., Five French versus eight French catheters and the Judkins technique. Advantages and limitations for studying coronary artery disease, *Int J Card Imaging*, 1988;3:61–5.
- Meyer P, Gervais A, Touati C, [Systematic use of 4 French catheters for left heart catheterisation and coronary angiographies], *Arch Mal Coeur Vaiss*, 1997;90:35–40.
- O'Sullivan JJ, McDonald K, Crean PA, et al., Cardiac catheterisation with 5 French catheters, *Br Heart J*, 1990;64:211–3.
- Metz D, Chapoutot L, Brasselet C, Jolly D, Randomized evaluation of four versus five French catheters for transfemoral coronary angiography, *Clin Cardiol*, 1999;22:29–32.
- Mehta H, Chatterjee T, Windecker S, et al., Four French catheters for diagnostic coronary angiography, *Catheter Cardiovasc Interv*, 2003;58:275–80.
- Dahdouh Z, Roule V, Grollier G, Downsizing from 6-French to 5-French guiding catheter after transradial coronary rotational atherectomy: a way to cross resistant calcified lesions, *Cardiovasc Revasc Med*, 2011;12:334–6.
- Matsukage T, Masuda N, Ikari Y, Successful transradial intervention by switching from 6 French to 5 French guiding catheter, *J Invasive Cardiol*, 2011;23:E153–5.
- Takeshita S, Tanaka S, Saito S, Coronary intervention with 4-French catheters, *Catheter Cardiovasc Interv*, 2010;75:735–9.
- Allie DE, Herbert, C.J., Walker, C.M, Automated contrast injection and targeted renal therapy: strategies to prevent contrast-induced nephropathy and to treat renal insufficiency in patients with peripheral arterial disease, *Vascular Disease Management*, 2006;3:1–5.
- McCullough PA, Wolyn R, Rocher LL, et al., Acute renal failure after coronary intervention: incidence, risk factors, and relationship to mortality, *Am J Med*, 1997;103:368–75.
- From AM, Bell MR, Rihal CS, Gulati R, Minimally invasive transradial intervention using sheathless standard guiding catheters, *Catheter Cardiovasc Interv*, 2011;78:866–71.
- Sciahbasi A, Mancone M, Cortese B, et al., Transradial percutaneous coronary interventions using sheathless guiding catheters: a multicenter registry, *J Interv Cardiol*, 2011;24:407–12.
- Takeshita S, Saito S, Transradial coronary intervention using a novel 5-Fr sheathless guiding catheter, *Catheter Cardiovasc Interv*, 2009;74:862–5.
- Gwon HC, Doh JH, Choi JH, et al., A 5Fr catheter approach reduces patient discomfort during transradial coronary intervention compared with a 6Fr approach: a prospective randomized study, *J Interv Cardiol*, 2006;19:141–7.
- Mizuno S, Takeshita S, Taketani Y, Saito S, Percutaneous coronary intervention using a virtual 3-Fr guiding catheter, *Catheter Cardiovasc Interv*, 2010;75:983–8.
- Stella PR, Kiemeneij F, Laarman GJ, et al., Incidence and outcome of radial artery occlusion following transradial artery coronary angioplasty, *Cathet Cardiovasc Diagn*, 1997;40:156–8.
- Pancholy S, Coppola J, Patel T, Roke-Thomas M, Prevention of radial artery occlusion-patent hemostasis evaluation trial (PROPHET study): a randomized comparison of traditional versus patency documented hemostasis after transradial catheterisation, *Catheter Cardiovasc Interv*, 2008;72:335–40.
- Baim DS, Knopf WD, Hinohara T, et al., Suture-mediated closure of the femoral access site after cardiac catheterisation: results of the suture to ambulate and discharge (STAND I and STAND II) trials, *Am J Cardiol*, 2000;85:864–9.
- Lehmann C, Hotaling M, Saving time, saving money: a time and motion study with contrast management systems, *J Invasive Cardiol*, 2005;17:118–21;quiz 122.
- Lim MJ, Early ambulation strategies with contrast management, *J Invasive Cardiol*, 2005;17:42–3; quiz 44.
- Seidelin PH, Adelman AG, Mobilization within thirty minutes of elective diagnostic coronary angiography: a feasibility study using a hemostatic femoral puncture closure device, *Journal of Interventional Cardiology*, 1997;10:409–15.
- Takeshita S, Shiono T, Takagi A, et al., Percutaneous coronary intervention using a novel 4-French coronary accessor, *Catheter Cardiovasc Interv*, 2008;72:222–7.
- Stefanini GG, Serruys PW, Silber S, et al., The impact of patient and lesion complexity on clinical and angiographic outcomes after revascularization with zotarolimus- and everolimus-eluting stents: a substudy of the RESOLUTE All Comers Trial (a randomized comparison of a zotarolimus-eluting stent with an everolimus-eluting stent for percutaneous coronary intervention), *J Am Coll Cardiol*, 2011;57:2221–32.
- Brown RI, MacDonald AC, Use of 5 French catheters for cardiac catheterisation and coronary angiography: a critical review, *Cathet Cardiovasc Diagn*, 1987;13:214–7.
- Kaluski E, Moussa ID, Heuser RR, et al., Automated contrast injectors for angiography: devices, methodology, and safety, *Catheter Cardiovasc Interv*, 2009;74:459–64.
- Kern MJ, Interventional and peripheral vascular procedures using contrast management: tips and techniques, *J Invasive Cardiol*, 2004;16:729–31; quiz 732.
- Brosh D, Assali A, Vaknin-Assa H, et al., The ACIST power injection system reduces the amount of contrast media delivered to the patient, as well as fluoroscopy time, during diagnostic and interventional cardiac procedures, *Int J Cardiovasc Intervent*, 2005;7:183–7.
- Arora P, Naik N, Bahl VK, et al., Coronary angiography using 4 French catheters with power injection: a randomized comparison with 6 French catheters, *Indian Heart J*, 2002;54:184–8.
- Chahoud G, Khoukaz S, El-Shafei A, et al., Randomized comparison of coronary angiography using 4F catheters: 4F manual versus "Acisted" power injection technique, *Catheter Cardiovasc Interv*, 2001;53:221–4.
- Durst R, Lotan C, Nassar H, et al., Comparison of 4 and 6 French catheters for coronary angiography: real-world modeling, *Isr Med Assoc J*, 2007;9:290–3.
- Kern MJ, Cohen M, Talley JD, et al., Early ambulation after 5 French diagnostic cardiac catheterisation: results of a multicenter trial, *J Am Coll Cardiol*, 1990;15:1475–83.
- Hou L, Wei YD, Song J, et al., Comparative study of 4Fr catheters using the ACIST variable rate injector system versus 6Fr catheters using hand manifold in diagnostic coronary angiography via transradial approach, *Chin Med J (Engl)*, 2010;123:1373–6.
- Anne G, Gruberg L, Huber A, et al., Traditional versus automated injection contrast system in diagnostic and percutaneous coronary interventional procedures: comparison of the contrast volume delivered, *J Invasive Cardiol*, 2004;16:360–2.
- Call J, Sacrinty M, Applegate R, et al., Automated contrast injection in contemporary practice during cardiac catheterisation and PCI: effects on contrast-induced nephropathy, *J Invasive Cardiol*, 2006;18:469–74.